

Unrecognized Bowen's disease in previously treated condylomata acuminata: indication of a common etiology?

Melita Vukšić Polić^{1,2}, Nataša Cutvarić³, Ksenija Marjanović^{4,5}, Martina Mihalj^{1,6} ✉

¹Department of Dermatology and Venereology, Osijek University Hospital, Osijek, Croatia. ²Department of Infectious Diseases, Dermatology, and Venereology, Faculty of Medicine, University of Osijek, Osijek, Croatia. ³Affidea Sveti Rok Polyclinic, Zagreb, Croatia. ⁴Clinical Department of Pathology and Forensic Medicine, Osijek University Hospital, Osijek, Croatia. ⁵Department of Pathological Anatomy and Forensic Medicine, Faculty of Medicine, University of Osijek, Osijek, Croatia. ⁶Department of Physiology and Immunology, Faculty of Medicine, University of Osijek, Osijek, Croatia.

Abstract

Bowen's disease (BD) is an intraepidermal squamous cell carcinoma (SCC) with the capacity to become invasive SCC giving rise to distant metastasis. In rare cases it can be associated with human papillomavirus (HPV) infection, specifically with HPV types 16, 18, 31, 32, and 34. Here we report a case of an immunocompetent white male, age 37, with an erythematous, irregularly-shaped patch in his suprapubic region, appearing 1 year after treatment for condylomata acuminata with cryotherapy and podophyllin in the same area. At the time of clinically active disease, a urethral smear was positive for high-risk HPV types. The lesion was considered a scar by several physicians because it emerged in an area of previous postinflammatory hyperpigmentation. The aim of this report is to raise awareness of the emerging causative association between anogenital HPV infection and the development of BD, which was the possible etiological agent in the case of the patient presented here. Hereby we also advocate primary preventive measures in terms of safe sexual habits and HPV vaccination.

Keywords: condylomata acuminata, human papillomavirus, Bowen's disease, sexually transmitted infections, carcinogenesis

Received: 15 June 2021 | Returned for modification: 20 July 2021 | Accepted: 1 December 2021

Introduction

Human papillomaviruses (HPVs) are small double-stranded non-enveloped deoxyribonucleic acid (DNA) viruses showing organotropism for stratified squamous epithelia (skin and mucosae) in humans (1, 2). HPVs belong to a much broader family of viruses called *Papillomaviridae* (PV), infecting not only humans, but also various animal species, including most mammals and some species of birds, reptiles, and fish (3). The number of PVs infecting humans is continuously growing, with currently more than 200 HPV types identified and organized into five major genera: alpha, beta, gamma, mu, and nu (4). According to data currently available from the International Human Papillomavirus Reference Center at www.hpvcenter.se (on August 16th, 2021), the genus gamma includes the majority of the known HPV types ($n = 99$), followed by the genera alpha ($n = 65$), beta ($n = 54$), mu ($n = 3$), and nu ($n = 1$). With few exceptions, most HPVs from the genus *Alphapapillomaviridae* (alpha HPVs) colonize and infect stratified squamous epithelia of the urogenital and oropharyngeal mucosa, whereas beta, gamma, mu, and nu HPVs are found in cutaneous epithelia (5). The majority of HPV infections of the skin and mucosa remain asymptomatic, whereas in the case of clinically manifested disease infected individuals commonly present with cutaneous or anogenital warts (1).

Alpha HPVs primarily cause sexually transmitted infections (STIs), but there is also firm scientific evidence for nonsexual routes of transmission (i.e., at birth or even through skin-to-skin contact) (6). Epidemiological studies in the United States have estimated that more than 80% of sexually active women and men will suffer from at least one HPV infection by age 45 (7); however, most infections remain subclinical and resolve spontaneously within 2 years (8). Anogenital warts, also referred as condylomata

ta acuminata, are common low-risk alpha HPV type-associated benign lesions in women and men (9). Nevertheless, it has been proposed that persistent skin lesions related to anogenital warts can facilitate entry of other HPV types into the cells, leading to malignant transformation of squamous epithelial tissue (10, 11).

In addition to being the most prevalent causative agent of STIs, HPV is also recognized as an important human carcinogen attributed to anogenital cancers (cervical, vaginal, vulvar, penile, and anal) and oropharyngeal cancers (tonsil, oral, and throat areas) (1). Based on epidemiological and biological data on HPV involvement in cervical/mucosal carcinogenesis, species from the genus alpha have been categorized as low-risk (6, 11, 42, 43, and 44) or high-risk (16, 18, 31, 33, 34, 35, 39, 45, 51, 52, 56, 58, 59, 66, 68, and 70) HPV types (12). According to the latest GLOBCAN report, cervical cancer is one of the leading malignancies in women, and it accounts for more than 600,000 cases of cancer annually in women worldwide, with an incidence rate of 13.3/100,000 (1.39%) and a mortality rate of 7.3/100,000 (0.82%) (6, 13). At the same time, HPV infection has been linked to the development of a subgroup of oropharyngeal cancers in women and men, with specific clinical presentation and response to surgical treatment and chemo-/radiotherapy (14).

Emerging evidence suggests an active role of HPV in the malignant transformation of the squamous epithelia of the skin, leading to the development of precancerous skin lesions or even skin cancers (15, 16). Precancerous lesions include Bowen's disease (BD), epidermodysplasia verruciformis, and bowenoid papulosis, and the most prevalent skin cancers associated with HPV infection are squamous cell carcinoma (SCC) and verrucous carcinoma. BD is an intraepidermal SCC, also referred to as SCC in situ, which may progress to invasive carcinoma, giving rise to local and/or distant metastasis. It was first described in 1912 by the American

✉ Corresponding author: martina.mihalj@mefos.hr

dermatologist John T. Bowen. The peak incidence of BD is in the 6th to 8th decade of life, with a slight female predominance (17). The lesions may occur at any site that is covered by stratified squamous epithelium, including the skin and part of the anogenital and oropharyngeal mucosal surfaces. The most common site is photoexposed skin of the head and neck, followed by the extremities in men and the lower limbs and cheeks in females. Genital BD is less common, and it has been strongly associated with high-risk HPV type 16 (18). Other alpha HPV types 16, 18, 33, 56, 58, 66, and 81 as well as multiple beta HPV types have also been found in BD occurring in extragenital locations (19).

Here we report the case of a 37-year-old immunocompetent male that developed BD in an area of previously treated condylomata acuminata associated with high-risk HPV genital infection. The aim of this report is to raise awareness of a plausible association between anogenital HPV infection and the development of BD.

Case report

In May 2016, a white male, age 37, was admitted to the Department of Dermatology and Venereology at Osijek University Hospital (Croatia) because of annular erythematous lesions in his

gluteal region. He also complained of erectile dysfunction lasting for 2 years and, in addition, clinical examination revealed a solitary irregularly shaped patch with a red to brown color, painless to palpation in the suprapubic region (Fig. 1A). According to his medical records, the patient was under supervision and treatment by a senior dermatologist for several years because of proven genital HPV infection manifested as anogenital warts (condylomata acuminata). In January 2015 he underwent surgical condyloma removal from the external urethral orifice, and the histopathological examination confirmed HPV infection (Fig. 2). The newly observed lesion was present in the suprapubic area, where the warts had previously been treated with podophyllin and cryotherapy around a year prior to his visit. According to the patient, the lesion appeared several months previously, and the lesion was characterized by several physicians as a scar. Posttreatment/postinflammatory residual hypopigmented macules at the sites of previous treatment were evident in the same area, as well as in other parts of perigenital region. According to his medical history, he was otherwise healthy, and the family history revealed that his mother suffered from melanoma. The patient denied symptoms or signs of inherited immunodeficiency or taking any medications that could affect the immune system. He reported more than five lifetime sexual partners and two recent sexual partners. All his partners were

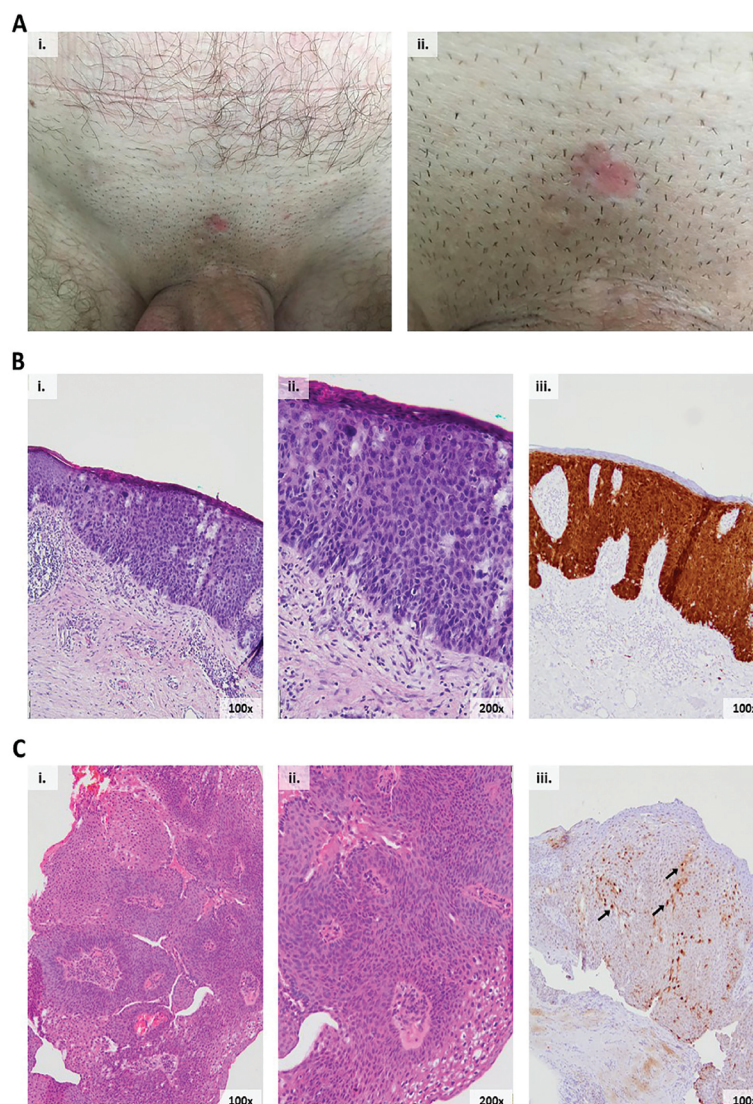


Figure 1 | Bowen's disease in an area of previously treated condylomata acuminata. (A i–ii) clinical presentation of Bowen's disease in the suprapubic region of a 37-year-old male patient; (B) histologic examination of the lesion biopsy: (i) H&E 100x and (ii) H&E 200x, (iii) immunohistochemical staining of p16(INK4a) (brown = examples of positive cells marked by arrows), p16(INK4a) positivity/overexpression correlates to HPV infection; (C) histologic examination of anogenital warts: (i) H&E 100x and (ii) H&E 200x, (iii) immunohistochemical staining of p16(INK4a).

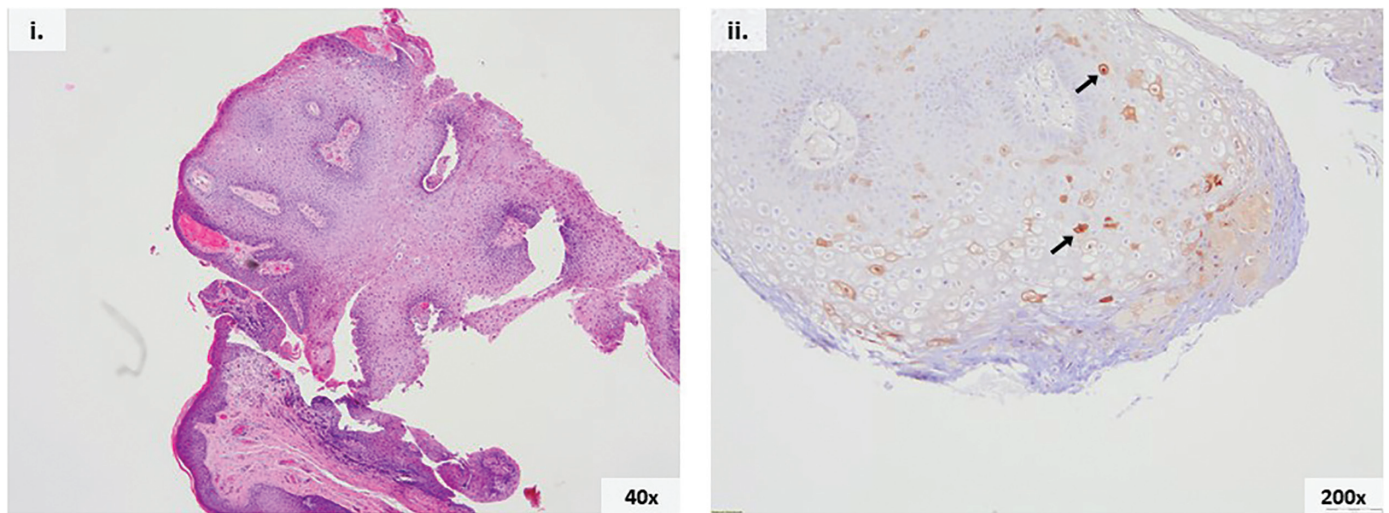


Figure 2 | Condyloma acuminatum removed from the external urethral orifice. Histologic examination of the condyloma removed from the urethral orifice: (i) H&E 40×, (ii) immunohistochemical staining of p16(INK4a), H&E 200× (brown = examples of positive cells marked by arrows).

heterosexual, and they practiced vaginal and oral sex. He denied having other STIs in the past. He was also tested for *Chlamydia trachomatis*, *Neisseria gonorrhoeae*, and *Mycoplasma genitalium*, other bacteria, and fungi, and the tests were all negative.

Further laboratory examinations revealed positive serology for *Borrelia burgdorferi*. A skin prick test was performed at our department, and it was positive for *Dermatophagoides pteronyssinus*. Molecular (PCR) HPV testing of urethral smear was positive for high-risk HPV types, including types 16, 18, 31, 33, 35, and 51 (AMPLICOR HPV test, Roche Diagnostics GmbH, Germany). HIV testing, as well as serology for hepatitis B, hepatitis C, and syphilis, were routinely performed, and all tests were negative. Following this, a skin biopsy of the suspicious lesion in the suprapubic area was obtained for histopathologic examination, and the result was suggestive of BD (Fig. 1B).

Surgical treatment and outcome

After receiving the results of the histopathological biopsy examination, the patient was referred to a plastic surgeon, who performed therapeutic excision of the lesion. Repeated histopathologic examination of the specimen confirmed BD. The lesion was about 1.8 × 1.5 cm in size, characterized by full-thickness epidermal dysplasia and cell atypia without evidence of cell invasion through the basement membrane (Fig. 1B). In addition, a strong p16(INK4a) block positivity was revealed by immunohistochemistry (CINtec®; Roche). Regional propagation of the tumorous tissue was excluded by ultrasound of the cervical, axillary, and inguinal lymph nodes.

The patient was given oral doxycycline therapy at a 2 × 100 mg regimen over 3 weeks to treat acute Lyme disease. At control visits after 2 months, the annular lesions were completely absent, and the postoperative wound healing was satisfactory.

Discussion

BD is a form of SCC in situ that may progress to invasive SCC. The etiology of BD is multifactorial and includes genetic factors, ultraviolet (UV) radiation, arsenic exposure (20), infection with high-risk HPV types (18, 21), and impaired immune functions (22). Both cutaneous and mucosa-associated HPV types, particularly types 16, 18, 31, 32, and 34, have been linked to BD, and epidermodysplasia verruciformis has been associated with cutaneous HPV

types 5, 8, 9, 12, 14, 15, 17, 19–25, 36–38, 46, 47, 49, and 50 (23). Non-melanoma skin cancers have also been correlated with HPV, primarily cutaneous HPV types 1, 5, 8, 9, 17, 20, 23, and 38 (24).

The most prevalent clinical manifestations of HPV infection are skin and anogenital warts mainly associated with low-risk HPV types. Namely, in more than 90% of condyloma acuminatum cases the (low-risk) HPV types 6 and 11 are found, whereas common warts are correlated with HPV types 1, 2, 3, 4, 27, and 57 (23). In a study by Löwhagen et al., high-risk HPV types (16, 18, 31, 33, and 35) were found in 24% of papular, 8% of acuminate, and 56% of macular penile lesions. In one-third of these lesions, histologically moderate to severe dysplasia was observed, and it was associated with infection caused by high-risk HPV types (25).

The male patient presented in this case report tested positive for HPV type 16 (urethral swab), coinciding with condylomata acuminata. After several years, he presented with SCC in situ in the same area, suggesting potential involvement of HPV in its development. Although the connection between HPV, especially HPV 16 and 18, and malignant transformation of condylomata acuminata in the anogenital region has been very well established (26, 27), the role of HPV in malignant transformation of cutaneous squamous epithelia and the underlying mechanisms is only emerging (28–30).

Mechanisms underlying malignant transformation of the squamous epithelia differ between the alpha HPVs and other (cutaneous) genera. Alpha HPVs are found to deliver E6 and E7 oncoproteins to the infected cells, leading to degradation of tumor suppressors p53 and retinoblastoma protein (pRB), and indirectly to the overexpression of cyclin-dependent kinase inhibitor p16(INK4a), resulting in cell cycle deregulation and cellular transformation (31, 32). The use of p16 expression as a surrogate marker of transcriptionally active HPV in cervical cancer management is based on this phenomenon. In the latter case, E7 and E6 proteins have a less permissive role. Beta HPVs promote proliferation and circumvention of cellular stresses induced by UV radiation or other carcinogenic agents in keratinocytes (16). Their role is especially important in the early stages of carcinogenesis, when they facilitate survival of cells damaged by UV light (usually undergoing apoptosis), and later they are important for sustaining the malignant phenotype, compatible with a “hit-and-run” mechanism. Furthermore, during chronic infection HPV is able to orchestrate immune responses resulting in impaired tumor antigen presentation by dendritic cells and recognition by cyto-

toxic T cells, hence facilitating tumor progression to invasiveness (33). Conversely, a recent study employing an animal model of HPV infection showed that cellular immunity against commensal papillomaviruses prevents the development of skin cancers in immunocompetent hosts (34). The same group of authors linked impaired immunity, rather than the oncogenic effect of HPVs, to a significantly increased risk of skin cancer in immunosuppressed individuals (34).

A local study from 2013, analyzing urethral swabs, reported that one-third of all HPV-positive samples from a male population in Osijek-Baranja County (Croatia) were positive for high-risk HPV types (35). The most common types were HPV 6 (24%) and 16 (17.8%). In the age group between 26 and 36 years, infection with high-risk HPV was associated with having more than one sexual partner per year, which indicates the importance of sexual habits and prevention measures in the community.

Malignant progression of SCC *in situ* into invasive carcinoma has been estimated at 3 to 5%. Although the rate of metastatic cutaneous SCC is low (about 4%), the mortality rate of people affected by metastatic cutaneous SCC is more than 70%, accounting for 20% of all deaths from skin cancers (36).

Endorsed guidelines for the follow-up of male patients with (high-risk) HPV-related anogenital disease, particularly in terms of emerging non-melanoma skin cancers in the adjacent area, are still lacking. In addition, due to the lack of a reliable sampling method for molecular HPV testing, there is still no HPV IVD test officially approved by the US Food and Drug Administration for men. The acetowhite (AW) test has high sensitivity for penile intraepithelial neoplasia, but it is much less reliable for skin lesions. Namely, AW showed high sensitivity only for hyperplastic warts and surrounding skin, whereas the sensitivity for other types of warts and subclinically infected areas was rather low. Hence, clinical examination and eventually skin biopsy remains the best diagnostic modality in the case of suspicious skin lesions, and the follow-up period is still to be determined by the physician, consid-

ering proven high-risk HPV infection in male patients and/or their sexual partners, patients' sexual behavior, adherence to therapy, and self-examination (37–39).

A limitation of this report is a lack of direct evidence of HPV in the BD lesion. Molecular analysis of the biopsy was not performed due to inaccessibility of the test. However, there are several indirect indicators suggesting a connection between HPV infection and BD. Here, BD occurred in an immunocompetent, otherwise healthy young individual in the same sun-protected body area of previous condylomata acuminata. Švajdler et al. reported high-risk alpha HPV or beta HPV positivity in 34.7% of BD lesions, with significantly higher prevalence in sun-protected sites (19). Immunohistochemical staining for p16(INK4a) revealed strong immunoreactivity in this case. Although p16(INK4a) staining has very high sensitivity and specificity for HPV infection in cervical and oropharyngeal mucosa, overexpression of p16(INK4a) in skin lesions varies considerably. Generally, BD shows strong p16(INK4a) immunoreactivity in 80 to 90% of cases, but the concordance with proven HPV infection is limited (19). Higher concordance was reported only in the case of HPV16, which adds to the possible causative connection between alpha HPV16 infection and the development of BD lesion in the case of our patient (40).

Conclusions

The aim of this case report is to raise awareness of the plausible causative association between anogenital HPV infection and the development of skin cancer. High-risk HPV types, primarily HPV16, are a rare cause of anogenital warts (condylomata acuminata); however, when present they can promote malignant transformation of squamous epithelium and the development of skin cancers. Hence, the development and promotion of local and national strategies for preventing HPV infection, including sex education and HPV vaccination, is warranted.

References

- Kombe Kombe AJ, Li B, Zahid A, Mengist HM, Bounda GA, Zhou Y, et al. Epidemiology and burden of human papillomavirus and related diseases, molecular pathogenesis, and vaccine evaluation. *Front Public Health*. 2021;8:552028.
- Manini I, Montomoli E. Epidemiology and prevention of human papillomavirus. *Ann Ig*. 2018;30:28–32.
- Della Fera AN, Warburton A, Coursey TL, Khurana S, McBride AA. Persistent human papillomavirus infection. *Viruses*. 2021;13:321.
- Egawa N, Egawa K, Griffin H, Doorbar J. Human papillomaviruses; epithelial tropisms, and the development of neoplasia. *Viruses*. 2015;7:3863–90.
- Gheit T. Mucosal and cutaneous human papillomavirus infections and cancer biology. *Front Oncol*. 2019;9:355.
- de Martel C, Plummer M, Vignat J, Franceschi S. Worldwide burden of cancer attributable to HPV by site, country and HPV type: worldwide burden of cancer attributable to HPV. *Int J Cancer*. 2017;141:664–70.
- Chesson HW, Dunne EF, Hariri S, Markowitz LE. The estimated lifetime probability of acquiring human papillomavirus in the United States. *Sex Transm Dis*. 2014;41:660–4.
- Cubie HA. Diseases associated with human papillomavirus infection. *Virology*. 2013;445:21–34.
- Sharma N, Sharma S, Singhal C. A comparative study of liquid nitrogen cryotherapy as monotherapy versus in combination with podophyllin in the treatment of condyloma acuminata. *J Clin Diagn Res*. 2017;11:WC01–5.
- Arroyo LS, Basaras M, Arrese E, Hernández S, Esteban V, Cisterna R. Distribution of genital human papillomavirus genotypes in benign clinical manifestations among men from northern Spain. *BMC Public Health*. 2016;16:81.
- Gómez DT, Santos JL. Human papillomavirus infection and cervical cancer: pathogenesis and epidemiology. In: Méndez Vilas A, editor. *Communicating current research and educational topics and trends in applied microbiology*. Badajoz: Formatex; 2007. p. 680–8.
- Burd EM. Human papillomavirus and cervical cancer. *Clin Microbiol Rev*. 2003;16:1–17.
- Cancer today [Internet]. [cited 2021 Jun 12]. Available from: <http://gco.iarc.fr/today/home>.
- Elrefaey S, Massaro MA, Chiocca S, Chiesa F, Ansarin M. HPV in oropharyngeal cancer: the basics to know in clinical practice. *Acta Otorhinolaryngol Ital*. 2014;34:299–309.
- Smola S. Human papillomaviruses and skin cancer. *Adv Exp Med Biol*. 2020;1268:195–209.
- Tommasino M. HPV and skin carcinogenesis. *Papillomavirus Res*. 2019;7:129–31.
- Eedy DJ, Gavin AT. Thirteen-year retrospective study of Bowen's disease in Northern Ireland. *Br J Dermatol*. 1987;117:715–20.
- Ikenberg H, Gissmann L, Gross G, Grussendorf-Conen EI, zur Hausen H. Human papillomavirus type-16-related DNA in genital Bowen's disease and in Bowenoid papulosis. *Int J Cancer*. 1983;32:563–5.
- Švajdler M, Mezencev R, Kašpírková J, Kacerovská D, Kazakov DV, Ondič O, et al. Human papillomavirus infection and p16 expression in the immunocompetent patients with extragenital/extraungual Bowen's disease. *Diagn Pathol*. 2016;11:53.

20. Hunt KM, Srivastava RK, Elmets CA, Athar M. The mechanistic basis of arsenicosis: pathogenesis of skin cancer. *Cancer Lett.* 2014;354:211–9.
21. Derancourt C, Mougin C, Chopard Lallier M, Coumes-Marquet S, Drobacheff C, Laurent R. Papillomavirus humains oncogènes révélés par technique d'hybridation in situ dans la maladie de Bowen extra-génitale [Oncogenic human papillomaviruses in extra-genital Bowen disease revealed by in situ hybridization]. *Ann Dermatol Venereol.* 2001;128:715–8. French.
22. Drake AL, Walling HW. Variations in presentation of squamous cell carcinoma in situ (Bowen's disease) in immunocompromised patients. *J Am Acad Dermatol.* 2008;59:68–71.
23. Brianti P, De Flammineis E, Mercuri SR. Review of HPV-related diseases and cancers. *New Microbiol.* 2017;40:80–5.
24. Nindl I, Gottschling M, Stockfleth E. Human papillomaviruses and non-melanoma skin cancer: basic virology and clinical manifestations. *Dis Markers.* 2007;23:247–59.
25. Löwhagen GB, Bolmstedt A, Ryd W, Voog E. The prevalence of “high-risk” HPV types in penile condyloma-like lesions: correlation between HPV type and morphology. *Genitourin Med.* 1993;69:87–90.
26. Blomberg M, Friis S, Munk C, Bautz A, Kjaer SK. Genital warts and risk of cancer: a Danish study of nearly 50 000 patients with genital warts. *J Infect Dis.* 2012;205:1544–53.
27. Creasman C, Haas PA, Fox TA, Balazs M. Malignant transformation of anorectal giant condyloma acuminatum (Buschke–Loewenstein tumor). *Dis Colon Rectum.* 1989;32:481–7.
28. Wang J, Aldabagh B, Yu J, Arron ST. Role of human papillomavirus in cutaneous squamous cell carcinoma: a meta-analysis. *J Am Acad Dermatol.* 2014;70:621–9.
29. Chahoud J, Semaan A, Chen Y, Cao M, Rieber AG, Rady P, et al. Association between β -genus human papillomavirus and cutaneous squamous cell carcinoma in immunocompetent individuals—a meta-analysis. *JAMA Dermatol.* 2016;152:1354–64.
30. Tampa M, Mitran CI, Mitran MI, Nicolae I, Dumitru A, Matei C, et al. The role of beta HPV types and HPV-associated inflammatory processes in cutaneous squamous cell carcinoma. *J Immunol Res.* 2020;2020:5701639.
31. Hong R. The utility of p16 immunostaining in cutaneous keratinocytic lesion. *Med Biol Sci Eng.* 2019;2:40–5.
32. Wang S, Zhuang X, Gao C, Qiao T. Expression of p16, p53, and TLR9 in HPV-associated head and neck squamous cell carcinoma: clinicopathological correlations and potential prognostic significance. *Onco Targets Ther.* 2021;14:867–77.
33. Smola S. Immunopathogenesis of HPV-associated cancers and prospects for immunotherapy. *Viruses.* 2017;9:254.
34. Strickley JD, Messerschmidt JL, Awad ME, Li T, Hasegawa T, Ha DT, et al. Immunity to commensal papillomaviruses protects against skin cancer. *Nature.* 2019;575:519–22.
35. Bosnjak Z, Perić M, Krizan IR, Dzijan S, Ruzman N, Pastuović T, et al. Prevalence and genotype distribution of high-risk human papillomavirus (HR HPV) in male genital samples of Osijek–Baranja County. *Coll Antropol.* 2013;37:1203–8.
36. Burton KA, Ashack KA, Khachemoune A. Cutaneous squamous cell carcinoma: a review of high-risk and metastatic disease. *Am J Clin Dermatol.* 2016;17:491–508.
37. Park IU, Palefsky JM. Evaluation and management of anal intraepithelial neoplasia in HIV-negative and HIV-positive men who have sex with men. *Curr Infect Dis Rep.* 2010;12:126–33.
38. Lopez-Diez E, Perez S, Carballo M, Iñarrea A, de la Orden A, Castro M, et al. Life-style factors and oncogenic papillomavirus infection in a high-risk male population. *PLoS One.* 2017;12:e0184492.
39. Hampras SS, Rollison DE, Giuliano AR, McKay-Chopin S, Minoni L, Sereday K, et al. Prevalence and concordance of cutaneous beta human papillomavirus infection at mucosal and cutaneous sites. *J Infect Dis.* 2017;216:92–6.
40. Geißler C, Tahtali A, Diensthuber M, Gassner D, Stöver T, Wagenblast J. The role of p16 expression as a predictive marker in HPV-positive oral SCCN—a retrospective single-center study. *Anticancer Res.* 2013;33:913–6.