

Trichophyton equinum infections among young wrestlers in Hungary

N. Erös, Zs. Károlyi and E. Molnár

S U M M A R Y

Epidemic-like tinea corporis and capitis cases were seen among a group of wrestlers aged from 8 to 17 years in Miskolc (Hungary) between July of 1997 and August of 1998. The fungal cultures revealed *Trichophyton equinum* as causative agent. Anthropophilic spreading of this zoophilic dermatophyte could be stemmed by using topical and systemic antimycotics and with special preventive measures.

Introduction

Trichophyton equinum is a zoophilic dermatophyte first described by Matruchot and Dassonville in 1898 and later by Gedoelst in 1902. It causes equine dermatophytosis that can rarely be transmitted to humans. Sporadic human infections occasionally occur in patients by contact with infected horses (1,2). Epidemic human infection was first described by Simon and Török in Budapest (Hungary) among young wrestlers in 1997 (3).

Material and methods

We revealed 28 cases of tinea corporis and 3 cases of tinea capitis among 8 to 17-year-old wrestlers in Miskolc (Hungary) between July of 1997 and August of 1998. The distribution of the affected sites is shown on

table 1. The erythematous, scaly, annular or gyrate plaques were 1 to 5 cm in diameter and alopecia was found on the scalp (Figures 1-2).

Direct microscopic examination of skin scrapings and hair samples revealed hyphae, many arthrospores within the hair and ectothrix spores around them. Samples were placed on Sabouraud's dextrose agar and on Mycosel fungal isolation media and the cultures were incubated at 26°C for 2 weeks. Initially white colonies developed with deep yellow reverse, later brownish due to the diffusion of the pigment (Figure 3). Lactophenol cotton blue microscopic preparations demonstrated septate, branching hyphae and numerous laterally placed microconidia. There were also chlamydospores in lateral and intercalary localizations (Figure 4). We found few stunted, cigar-shaped macroconidia consisting of 3 to 5 cells with thin, plain wall. The in vitro hair

**K E Y
W O R D S**

**Trichophyton
equinum,
wrestlers,
anthropophilic
spreading,
Hungary**

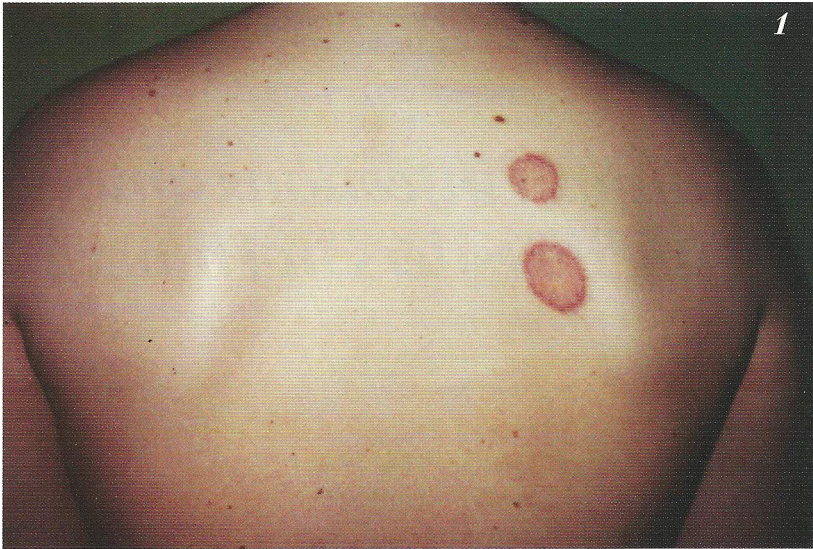

Figure 1. Annular, erythematous lesions on the back.

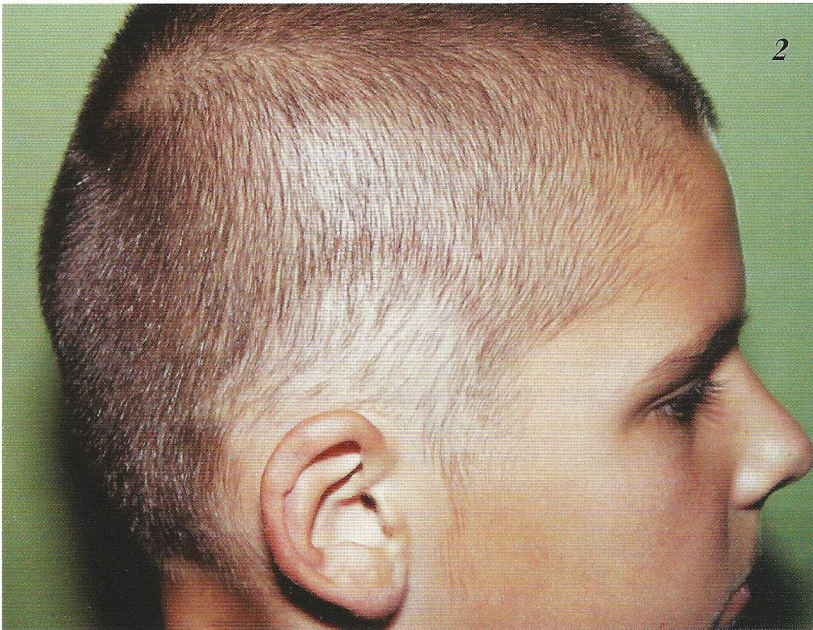


Figure 2. Typical mycotic lesion on the scalp.

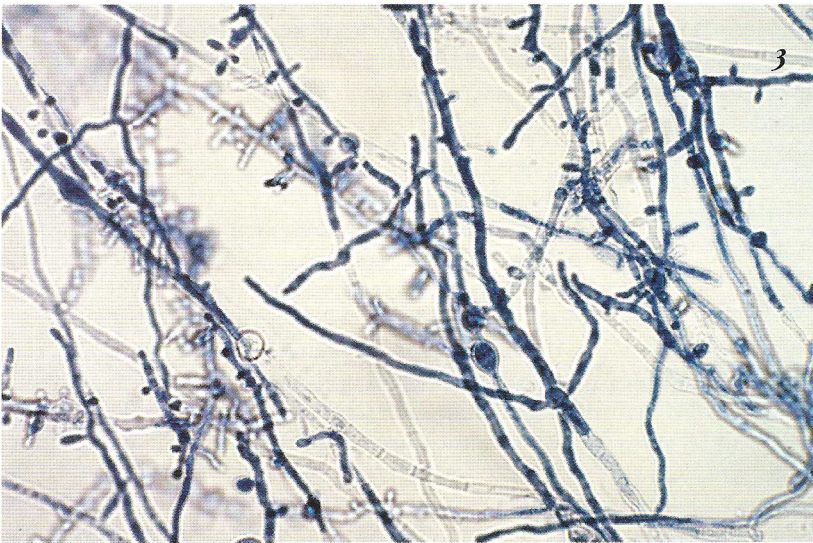


Figure 3. Microconidia and chlamydospores in the lactophenol cotton blue microscopic preparation.

Figure 4. *Trichophyton equinum* colonies on Mycosel agar.

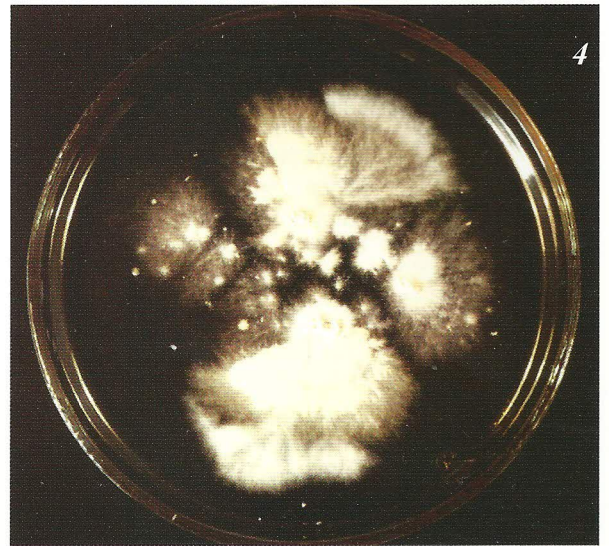


Table 1. Distribution of the affected sites.

Distribution of the affected sites	
scalp	3
face	3
neck	1
trunk	11
upper extremities	10
lower extremities	3

perforation tests were negative.

According to these morphological features the pathogen was identified as *Trichophyton equinum* and can be differentiated from other similar dermatophytes such as *Trichophyton mentagrophytes*, *T. rubrum*, *T. erinacei* and *T. interdigitale*. Because it did not require nicotinic acid for its growth, a rare variant was diagnosed namely *Trichophyton equinum var. autotrophicum*. Only 6 cultures were found to be positive out of 31 cases, the negative results were probably due to the previous antimycotic treatment.

Only topical antimycotic treatment was introduced in cases of tinea corporis using clotrimazole, ciclopirox olamine, econazole, ketoconazole, natamycin and ter-

binafine. In cases of tinea capitis topical ciclopirox olamine and oral terbinafine treatment was successful after three months.

In order to prevent the infection we recommended regular use of ketoconazole containing shampoo for showering and washing hair both in the infected and non-infected persons. Disinfection of the wrestling mats and other sports implements was necessary to stop the source of infection.

Discussion

Infection of wrestlers by herpes simplex virus and dermatophytes is a specific problem, so they have their own terminology: "herpes gladiatorum" and "tinea corporis gladiatorum". Few reports were published about mycotic epidemics among wrestlers since 1966, mainly originating from the USA. The pathogen agent was *Trichophyton tonsurans* in almost every case (Table 2). In Hungary *Trichophyton equinum* infections were first reported by Simon and Török in 1997; it started among young wrestlers in Budapest (3). We suppose that the infection spread from there to our city during wrestling matches and common trainings.

Table 2. Major mycotic epidemics among wrestlers.

DATE	PLACE	PATIENTS	CASES	LOCALISATION	PATHOGEN	AUTHORS
1966.	Sweden	wrestlers			<i>Trichophyton</i>	Frisk, Heilborn, Melon (4)
1992.	New York, USA	student wrestlers			<i>Trichophyton tonsurans</i>	Stiller, Klein, Dorman (5)
1992.	Maryland, USA	9 to 15 year old wrestlers	5/8	tinea corporis, capitis	<i>Trichophyton tonsurans</i>	Cohen, Schmidt (6)
1992.	New Jersey, USA	university wrestlers			<i>Trichophyton tonsurans</i>	Rosenthal, Sanguenza, Klein (7)
1992-93.	Alaska, USA	14 to 19 year old wrestlers	10/21	tinea corporis	<i>Trichophyton tonsurans</i>	Beller, Gessner (8)
1993.	Boston, USA	18 to 21 year old wrestlers	4	tinea corporis	?	Werninghaus (9)
1993.	Sweden	wrestlers	19		<i>Trichophyton tonsurans</i>	Hradil, Hersle, Nordin, Faergemann (10)
1994-96.	Budapest, Hungary	5 to 16 year old wrestlers	24/44	tinea corporis, capitis	<i>Trichophyton equinum var. autotrophicum</i>	Simon, Török (3)
1997-98.	Miskolc, Hungary	8 to 17 year old wrestlers	6/31	tinea corporis, capitis	<i>Trichophyton equinum var. autotrophicum</i>	Erös, Károlyi, Molnár

Although *Trichophyton equinum* is a zoophilic dermatophyte, the spread of this infection seems to be rather anthropophilic than zoophilic, because none of the wrestlers had contact with infected horses and the infection was cumulated in a closed community. We did not find any infected personal belongings or sports implements, therefore their etiological role as a source of infection could be excluded. The infection spread from one wrestler to the other due to the close skin contact, sweating and possible excoriations.

These mycotic infections were only observed in the age group of 8 to 17 years. The infection was not transmitted to the adults training with the young

wrestlers. *Trichophyton equinum* does not seem to be a highly pathogenic dermatophyte. The glabrous skin mycoses produced only mild symptoms and responded well to topical antimycotic treatment. In one of the three scalp mycoses a severe inflammatory reaction was observed which required a three months-long oral terbinafine and topical antimycotic treatment for cure.

The epidemic could only be stemmed by screening all members of the wrestling team and treating all of the infected patients at the same time. The use of antimycotic shampoo for all members, disinfection of the sports implements and clothes were our successful preventive measures to stop the epidemic.

REFERENCES

1. Shwayder T, Andrae M, Babel D. *Trichophyton equinum* from riding bareback: first reported U.S. case. *J Am Acad Dermatol* 1994; 30: 785-7.
2. Brasch J, Holst RE, Christophers E. Tinea durch *Trichophyton equinum*. *Hautarzt* 1998; 49: 397-402.
3. Simon G, Török I. *Trichophyton equinum* var. *autotrophicum* infection at wrestlers. *Börge Vener Sze* 1997; 73: 197-202.
4. Frisk A, Heilborn H, Melon B. Epidemic occurrence of trichophytosis among wrestlers. *Acta Derm Venereol (Stockh)* 1966; 46: 453-6.
5. Stiller MJ, Klein WP, Dorman RI, Rosenthal S. Tinea corporis gladiatorum: an epidemic of *Trichophyton tonsurans* in student wrestlers. *J Am Acad Dermatol* 1992; 27: 632-3.
6. Cohen BA, Schmidt C. Tinea gladiatorum (letter). *N Engl J Med* 1992; 327: 820.
7. Rosenthal S et al. Brote epidemico de tinea corporis producido por *Trichophyton tonsurans* en estudiantes universitarios practicantes de lucha greco-romana. *Piel* 1992; 7: 483-5.
8. Beller M, Gessner BD. An outbreak of tinea corporis gladiatorum on a high school wrestling team. *J Am Acad Dermatol* 1994; 31: 197-201.
9. Werninghaus K. Tinea corporis in wrestlers (letter). *J Am Acad Dermatol* 1993; 28: 1022-3.
10. Hradil E et al. An epidemic of tinea corporis caused by *Trichophyton tonsurans* among wrestlers in Sweden. *Acta Derm Venereol* 1995; 75: 305-6.

A U T H O R S ' A D D R E S S E S *Nóra Erös, MD, Department of Dermatology, Semmelweis Hospital, Csaba kapu 6, H-3501 Miskolc, Hungary*
Zsuzsánna Károly MD, same address
Erzsébet Molnár, same address