

Linear IgA bullous dermatosis in an acute myeloid leukemia patient: a rare case report

Deisy Vania Kianindra¹, Amelia Rosa^{1✉}, Dina Pebriany¹, Wiwiek Dewiyanti¹, Asnawi Madjid¹

¹Department of Dermatology and Venereology, Faculty of Medicine, Hasanuddin University, Makassar, Indonesia.

Abstract

Linear IgA bullous dermatosis (LABD) is a rare autoimmune bullous disease characterized by linear IgA deposition along the skin basal membrane. In children, LABD classically presents with a “cluster of jewels” appearance, whereas in adults the classic presentation is itchy papules with tense vesicles and bullae on an erythematous base. We report the case of a 41-year-old woman with LABD that we suspect was induced by acute myeloid leukemia presenting with multiple vesicles and bullae that coalesced, forming the typical clinical manifestation of LABD and confirmed with histopathological and direct immunofluorescence. The patient was treated with a combination of oral and topical corticosteroids with excellent results.

Keywords: bullous, dermatosis, LABD, myeloid leukemia

Received: 10 December 2022 | Returned for modification: 17 January 2023 | Accepted: 7 February 2023

Introduction

Jabłońska's linear IgA dermatosis and Duhring's dermatitis herpetiformis were not distinguished until 1976. Before that time, there was confusion concerning the diagnostic criteria, nomenclature, and classification of this entity (1). Linear IgA bullous dermatosis (LABD) is a rare autoimmune bullous disease characterized by linear deposition of IgA along the skin basement membrane. LABD is usually idiopathic but may be associated with drugs, lymphoproliferative disorders, carcinoma, and systemic disease (2, 3). LABD has been reported to be induced by various drugs (4, 5). Histopathologically, LABD is characterized by the formation of subepidermal bullae with a predominantly neutrophilic infiltrate in the skin of the lesion. In LABD, the characteristic immunopathological finding is the presence of basement membrane zone (BMZ)-specific IgA class antibodies in a linear distribution on direct immunofluorescence (DIF) of perilesional skin in the absence of other immunoglobulin (6). However, these findings can also be seen in other subepidermal bullous diseases such as bullous pemphigoid (BP) and dermatitis herpetiformis (DH) (4, 7–9).

Clinical differences in typical cases of DH and BP are evident. In DH, characteristic polymorphous papulovesicular lesions, chiefly localized on the buttocks, elbows, knees, back, and head, are present. In BP, large, tense, sometimes hemorrhagic bullae can be present in any location. DH is usually related to celiac disease, whereas LABD and BP are usually related to tumor pathologies. Pruritus, if present in BP, is less severe than in DH, in which a burning sensation is also a characteristic feature. Dermatitis herpetiformis and bullous pemphigoid also differ considerably in histological features. In DH, polymorphonuclear microabscesses in dermal papillae around the bullae are highly characteristic. In BP there are subepidermal bullae either with or without inflammatory infiltrates, and a perivascular infiltrate, which also includes eosinophils (1, 10).

The distinction between BP and DH is further strengthened by differences in immunofluorescence findings. In DH, the characteristic immunopathological findings are deposits of granular IgA in the dermal papillae surrounding skin lesions without circulat-

ing antibodies. In the vast majority of cases of BP, IgG and complement are bound in vivo at the dermal-epidermal junction (1). Diagnosis of LABD is difficult due to the similarity of its clinical symptoms with other bullous diseases. Therefore, further diagnostic examination tools such as DIF are needed to confirm the diagnosis. Here we report a case of LABD in a 41-year-old woman that we suspect was induced by acute myeloid leukemia.

Case report

A 41-year-old woman with acute myeloid leukemia presented to the dermatology and venereology department with multiple blisters and crusting on her back and abdomen that had appeared 1 month prior. In addition, multiple red papules had started to appear on her extremities. The symptoms were accompanied by itching and burning sensations. The patient admitted taking antibiotics and analgesics in the previous 2 weeks. A history of similar complaints was denied.

Physical examination showed vital signs within normal limits. Dermatological examination on the posterior truncal region revealed clusters of tense erythematous vesicles and bullae resembling a “cluster of jewels” along with crusting and erosion (Fig. 1A–B). No abnormalities were found on the mucous membrane of the eyes, mouth, or genitals. Based on history and physical examination, the patient was differentially diagnosed with LABD, dermatitis herpetiformis, and bullous pemphigoid.

Histopathological examination with hematoxylin and eosin (H&E) staining revealed inflammation on the superficial dermis with perivascular and interstitial lymphocyte infiltration mixed with neutrophils; the dermis area appeared edematous. These features, although not pathognomonic, may support the diagnosis of LABD (Fig. 2A–C). Subsequent DIF examination found weak and focal IgA deposits at the dermal-epidermal junction. No IgG, IgM, or C deposits were found. These results confirmed the diagnosis of LABD (Fig. 3).

The patient was then treated with 16 mg oral methylprednisolone b.i.d., 10 mg oral cetirizine daily, and a topical combination of 0.1% betamethasone cream and 2% fusidic acid cream applied

✉ Corresponding author: ameliarosa1708@gmail.com

twice daily. Three days after treatment, complaints of itching improved. In addition, the cutaneous lesions started to resolve. At a 1-month follow-up, the patient felt no pain or pruritus. Improve-

ments were also seen on the lesions, with resolution of the bullae and vesicles leaving only hyperpigmented macules and slight crusting (Fig. 4).

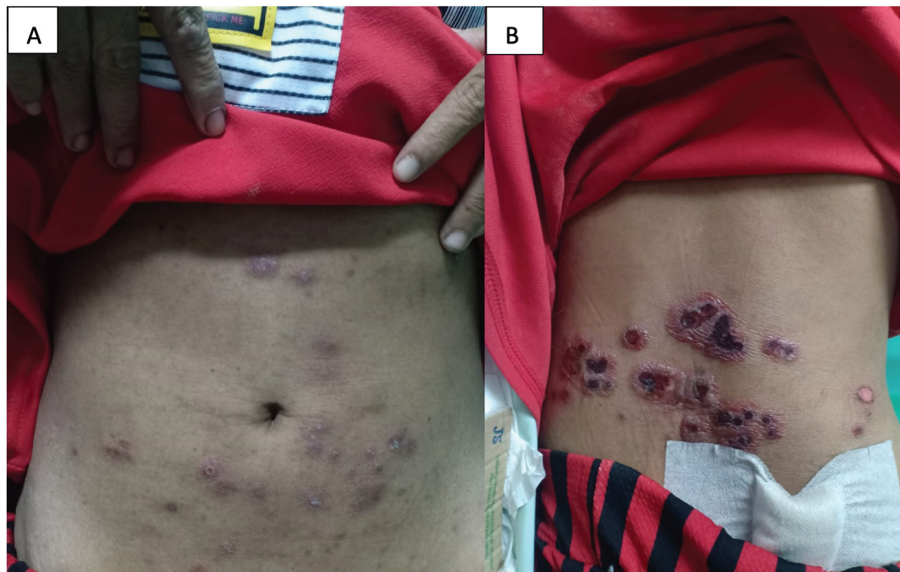


Figure 1 | Multiple clusters of tense erythematous vesicles and bullae on the abdomen and posterior truncal region resembling a “cluster of jewels” along with prominent erythematous crusting (A–B).

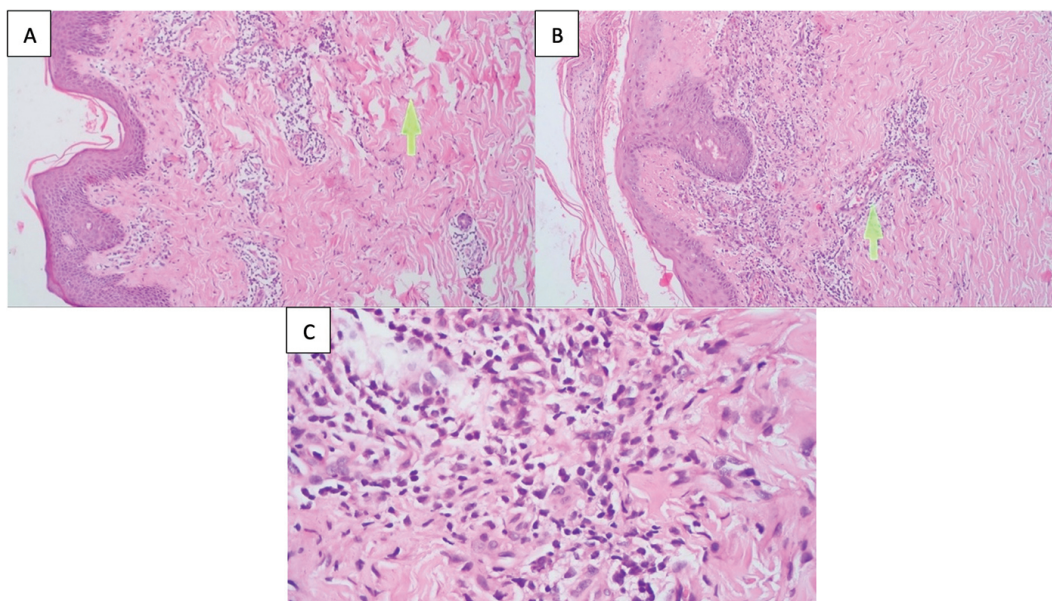


Figure 2 | Edema of the dermis (A, 40×); lymphocyte and neutrophil infiltration (B, 40×); along with perivascular lymphocytes (C, 200×).

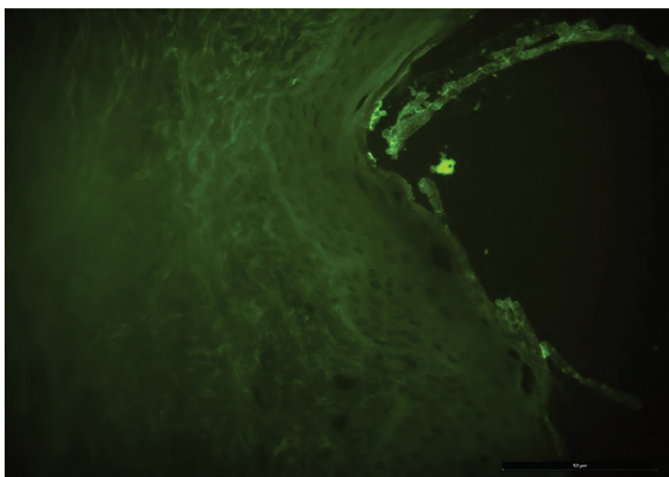


Figure 3 | The direct immunofluorescence result found IgA deposition on the dermal-epidermal junction.

Discussion

LABD is a rare subepidermal bullous disease with an incidence of approximately 0.5 cases per million in southwestern Europe. The disease has a higher occurrence in children and the elderly (> 60 years). The disease has no gender or racial predominance (4, 11). The clinical presentation of LABD is usually heterogeneous, mostly involving the skin, although oral manifestations have occasionally been reported (11, 12). Although very rare, mucosal lesions can act as the single clinical presentation and may precede cutaneous lesions (12, 13). Because there are various differential diagnoses for bullous diseases, a thorough history-taking and physical examination combined with confirmation by histopathology and DIF were necessary to exclude potential differential diagnoses such as BP and epidermolysis bullosa acquisita.

In our patient, dermatological examination revealed multiple

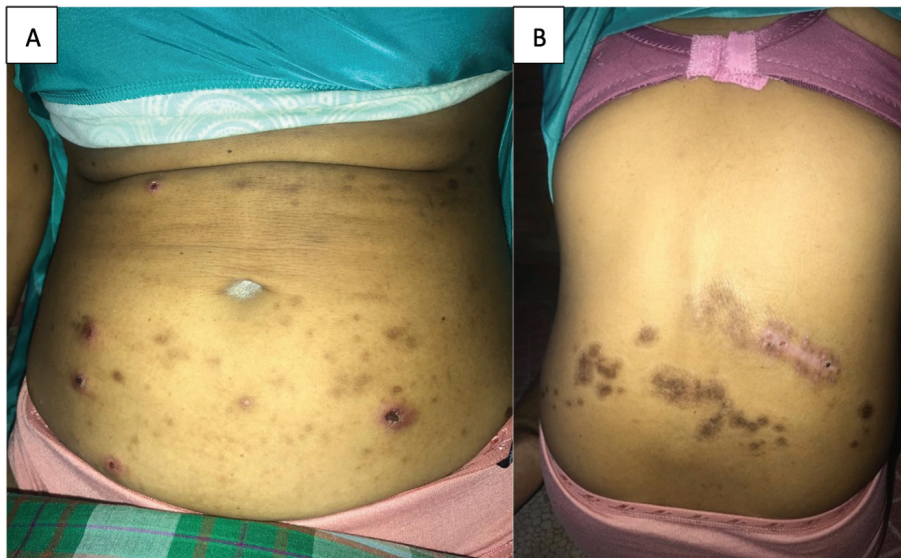


Figure 4 | Resolution of bullae and vesicles leaving hyperpigmented macules and plaques along with slight crusting after 1 month of treatment (A–B).

vesicles on the abdomen alongside numerous vesicles and bullae that coalesced on the posterior truncal region resembling a “cluster of jewels” along with crusting. These findings were accompanied by pruritus and a burning sensation. The “cluster of jewels” appearance is a typical characteristic of LABD (7, 11, 14, 15).

The exact pathogenesis of LABD is yet to be established. It is thought to be drug-related or a systemic autoimmune disease. The association between LABD and drug exposure, most commonly vancomycin, has been widely reported (4, 5, 12, 16). However, we suspect that the cause of LABD in our patient was due to acute myeloid leukemia. This is consistent with literature that reports a correlation between malignancies and LABD (7, 11, 17). LABD can also be induced by tumor pathologies, in particular of the blood. There are reports of LABD associations with Hodgkin’s lymphoma (18), angioimmunoblastic T-cell lymphoma (19), acute lymphoblastic leukemia (20) and its chronic form (chronic lymphocytic leukemia) (21), and chronic myeloid leukemia (22). Therefore, it is emphasized that a case of LABD associated with acute myeloid leukemia has previously been described. However, whether LABD is a paraneoplastic manifestation of lymphoproliferative disease triggered by abnormal immune processes, has yet to be investigated (23).

Histopathological examination of our patient showed inflammation in the superficial dermis in the form of perivascular and interstitial lymphocyte infiltration mixed with neutrophils, with edema in the dermis. This is in accordance with the literature, which reports that the histopathological picture in LABD is the presence of subepidermal bullae with dominant infiltrates of neutrophils and eosinophils, and mononuclear cells (4, 24, 25). To confirm the diagnosis, DIF was performed, showing weak and focal IgA deposits at the dermal-epidermal junction, which confirmed the diagnosis of LABD (4, 11, 12). The gold standard for the diagnosis of LABD is the presence of BMZ-specific IgA class antibodies in a linear distribution on DIF of perilesional skin in the absence of other immunoglobulins. The antibodies are usually IgA1 subclass, but IgA2 BMZ-specific antibodies have also been described in a minority of cases. The majority of these antibodies bind to the epidermal side of BMZ-split human skin, with a minority of these antibodies binding to the dermal side. Occasionally, antibody binding to both sides of the split can be observed (6). This is why sometimes one can only find weak and focal IgA deposits at the dermal-epidermal junction.

The differential diagnosis for LABD should include other vesiculobullous diseases such as dermatitis herpetiformis, bullous pemphigoid, epidermolysis bullosa acquisita, bullous impetigo, pemphigus vulgaris, erythema multiforme, and toxic epidermal necrolysis (26).

Dermatitis herpetiformis has very similar findings on immunohistochemical staining, with the main difference being the granular deposition of IgA, instead of linear deposition as in LABD. Bullous pemphigoid is characterized by linear deposits of IgG along the epidermal BMZ. Unfortunately, at times, there can be a mixed linear deposition of both IgG and IgA at the basement membrane, creating a diagnostic conundrum. Different options exist as far as classifying this specific deposition pattern as either bullous pemphigoid or LABD (26).

Dapsone is considered the first-line therapy for LABD. Its efficacy has been proven as monotherapy or in combination with other drugs, such as corticosteroids, nicotinamide, and antibiotics. In addition, new and safe alternative therapies, such as intravenous immunoglobulin and immunoadsorption, have been used successfully over the past 10 years. (4, 12, 25). However, because dapsone was not available at our center, in this case the patient was treated using oral corticosteroids with the recommended dosage equivalent to 0.5 to 2 mg/kgBW prednisone daily (12). The patient weighed 50 kg, and so a dosage of 36 mg daily seemed to be suitable treatment for the patient, and this was followed by significant clinical improvement (12, 27). Topical corticosteroids were also applied in our patient along with topical antibiotics to prevent infections. A study by Saenz et al. reported that, when treatment with dapsone is not available, topical corticosteroids can be an alternative, either alone or in conjunction with other treatments (28). After 1 month of treatment, the lesions mostly resolved, leaving only hyperpigmented macules and plaques along with slight crusting.

Conclusions

LABD is a rare bullous disease that can mimic other dermatoses. Clinical manifestation of a “cluster of jewels” appearance along with histopathological and DIF features can aid in diagnostic confirmation. In our case, a combination of oral and topical corticosteroids provided excellent results.

References

1. Jablonska S, Chorzelski T, Beutner E, Maciejowska E, Rzeska G. Dermatitis herpetiformis and bullous pemphigoid. *Arch Dermatol*. 1976;112:45–8.
2. Maalouf N, Hanna D. Linear IgA bullous dermatosis successfully treated with omalizumab: a case report. *JAAD Case Rep*. 2019;5:966–9.
3. Yamagami J, Nakamura Y, Nagao K, Funakoshi T, Takahashi H, Tanikawa A. Vancomycin mediates IgA autoreactivity in drug-induced linear IgA bullous dermatosis. *J Invest Dermatol*. 2018;138:1473–80.
4. Chaudhari S, Mobini N. Linear IgA bullous dermatosis: a rare clinicopathologic entity with an unusual presentation. *J Clin Aesthet Dermatol*. 2015;8:43–6.
5. Jha P, Swanson K, Stromich J, Michalski B, Olasz E. A rare case of vancomycin-induced linear immunoglobulin A bullous dermatosis. *Case Rep Dermatol Med*. 2017;2017:7318305.
6. Egan CA, Zone JJ. Linear IgA bullous dermatosis. *Int J Dermatol*. 1999;38:818–27.
7. Genovese G, Venegoni L, Fanoni D, Muratori S, Berti E, Marzano A. Linear IgA bullous dermatosis in adults and children: a clinical and immunopathological study of 38 patients. *Orphanet J Rare Dis*. 2019;14:115.
8. Antiga E, Caproni M, Fabbri P. Linear immunoglobulin a bullous dermatosis: need for an agreement on diagnostic criteria. *Dermatology*. 2013;226:329–32.
9. Venning V. Linear IgA disease: clinical presentation, diagnosis, and pathogenesis. *Dermatol Clin*. 2011;29:453–8.
10. Ständer S, Hammers CM, Vorobyev A, Schmidt E, Zillikens D, Ghorbanalipour S, et al. The impact of lesional inflammatory cellular infiltrate on the phenotype of bullous pemphigoid. *J Eur Acad Dermatol Venereol*. 2021 Aug 1;35:1702–11.
11. Kashyap R, Nair G, Kashyap R. Dilemmatic presentation of linear IgA disease: a case report. *Stomatol Dis Sci*. 2017;1:93–6.
12. Fortuna G, Marinkovich M. Linear immunoglobulin A bullous dermatosis. *Clin Dermatol*. 2012;30:38–50.
13. Souza B, Fregonesi N, Tebcherani A, Sanchez A, Aoki V, Fernandes J. Linear IgA bullous dermatosis: report of an exuberant case. *An Bras Dermatol*. 2013;88:67–70.
14. Lammer J, Hein R, Roenneberg S, Biedermann T, Volz T. Drug-induced linear IgA bullous dermatosis: a case report and review of the literature. *Acta Derm Venereol*. 2019;99:508–15.
15. Nicholas M, Rao C, Hall R. Linear immunoglobulin A dermatosis and chronic bullous disease of childhood. In: Kang S, Amagai M, Bruckner AL, Enk AH, Margolis DJ, McMichael AJ, et al., editors. *Fitzpatrick's dermatology*. 9th ed. New York: McGraw Hill; 2019. p. 992–1001.
16. Nartker N, Kudlak N, Crowe D. Linear IgA bullous dermatosis protracted by vancomycin-loaded bone cement. *JAAD Case Rep*. 2019;5:234–6.
17. McDonald H, York N, Pandya A. Drug-induced linear IgA bullous dermatosis demonstrating the isomorphic phenomenon. *J Am Acad Dermatol*. 2010;62:897–8.
18. Jacyk WK, Nagel GJ, Van Der Hoven AE. Linear IgA dermatosis and Hodgkin's lymphoma—report of a case in an African and review of the literature. *J Dermatol*. 1990;17:633–7.
19. Colmant C, Camboni A, Dekeuleeneer V, Marot L, Dachelet C, Baeck M. Linear IgA dermatosis in association with angioimmunoblastic T-cell lymphoma infiltrating the skin: a case report with literature review. *J Cutan Pathol*. 2020;47:251–6.
20. Polat M, Lenk N, Kurekci E, Oztas P, Artuz F, Alli N. Chronic bullous disease of childhood in a patient with acute lymphoblastic leukemia. *Am J Clin Dermatol*. 2007;8:389–91.
21. Tiger JB, Rush JT, Barton DT, Danilov AV, Chapman MS. Urticarial linear IgA bullous dermatosis (LABD) as a presenting sign of chronic lymphocytic leukemia (CLL). *JAAD Case Rep*. 2015;1:412.
22. Schultewolter T, Goos M, Dissemund J. Linear IgA dermatosis in an immunosuppressed patient after allogeneic bone marrow transplantation. *J Eur Acad Dermatol Venereol*. 2004;18:721–5.
23. Usmani N, Baxter K, Child J, Sheehan-Dare R. Linear IgA disease in association with chronic lymphocytic leukaemia. *Br J Dermatol*. 2004;151:710–1.
24. Vale E, Dimatos O, Porro A, Santi C. Consensus on the treatment of autoimmune bullous dermatoses: dermatitis herpetiformis and linear IgA bullous dermatosis—Brazilian Society of Dermatology. *An Bras Dermatol*. 2019;94:48–55.
25. Diaz M, Morita L, Ferrari B, Sartori S, Greco M, Sobrevias B. Linear IgA bullous dermatosis: a series of 17 cases. *Actas Dermosifiliogr*. 2019;110:673–80.
26. Bernett CN, Fong M, Yadlapati S, Rosario-Collazo JA. Linear IgA dermatosis. 2022. In: StatPearls [Internet]. Treasure Island (FL): StatPearls Publishing; 2022.
27. Tsai I, Chu C, Chen H, Wang L, Chiu H. Linear IgA bullous dermatosis: a clinical study of 16 cases at National Taiwan University Hospital. *Dermatologica Sin*. 2010;28:21–6.
28. Gil Sáenz F, Durán Urdániz G, Fernández Galar M, Ballester J, Herrero Varasa A, Garcés Bordege R. Topical corticosteroids as a therapeutic alternative in linear immunoglobulin A bullous dermatosis in childhood: case report. *Arch Argent Pediatr*. 2016;114:e440–3.