

Pembrolizumab-induced lichen planus in patients with metastatic melanoma: a report of two cases and prognostic implications of cutaneous immune-related adverse events

Tanja Tirnanić¹✉, Danica Todorović², Nataša Vidović³, Mirjana Balić⁴, Nenad Petrov⁵, Lidija Kandolf¹, Željko Mijušković¹

¹Department of Dermatology and Venereology, School of Medicine, Military Medical Academy, Belgrade, Serbia. ²Dermatology Clinic, Niš Clinical Center, Niš, Serbia. ³Pathology Clinic, Niš Clinical Center, Niš, Serbia. ⁴Oncology Clinic, Niš Clinical Center, Niš, Serbia. ⁵Institute of Pathology, School of Medicine, Military Medical Academy, Belgrade, Serbia.

Abstract

Patients receiving immune checkpoint inhibitors (ICIs) commonly experience cutaneous immune-related adverse events (irAEs). We present two cases, a 51-year-old female and a 70-year-old male, that were undergoing treatment with pembrolizumab for metastatic melanoma and developed scaly, erythematous papules on their skin. Following skin biopsies, histological analysis confirmed the diagnosis of lichen planus. In the first patient, acitretin at a dosage of 25 mg/day was administered for 6 months, resulting in complete resolution of lichen lesions. Imaging scans showed no signs of melanoma. The second patient was treated with topical betamethasone dipropionate ointment for several weeks, which led to a favorable therapeutic response. During follow-up, a thoracic CT scan showed several micronodular lesions in the right lung, whereas brain and abdomen CT scans showed no signs of the disease. Lichen planus is not a commonly reported irAE in patients treated with ICIs. This report underscores the importance of conducting skin biopsies in patients receiving ICI therapy and highlights the potential prognostic importance of skin irAEs in patients with melanoma receiving such treatment.

Keywords: immune checkpoint inhibitors, immune-related adverse events, pembrolizumab, lichen planus, metastatic melanoma

Received: 14 July 2023 | Returned for modification: 10 August 2023 | Accepted: 14 August 2023

Introduction

The landscape of treating metastatic melanoma has been revolutionized by immune checkpoint inhibitors (ICIs) such as pembrolizumab, an anti-PD-1 antibody, which has significantly improved overall survival rates to 40% over a span of 5 years in treatment-naïve metastatic melanoma patients (1). However, the administration of ICIs is often linked to the occurrence of immune-related adverse events (irAEs). These adverse events commonly affect various organs, including the skin, gastrointestinal organs, endocrine glands, and lungs (2, 3). Among the irAEs, pruritus, photosensitivity, xerosis cutis, lichenoid drug reactions, eczema, psoriasis, and vitiligo are the most frequently reported manifestations (4, 5). Unlike lichenoid drug eruptions and vitiligo, lichen planus is not a commonly reported irAE in patients treated with ICIs. This report presents two cases of pembrolizumab-induced lichen planus in patients being treated for metastatic melanoma.

Case 1

A 51-year-old female with no family history of skin cancer underwent a primary excision of melanoma from her left forearm in 2006. In February 2012, the patient reported a palpable tumor mass in her left axilla and two subcutaneous nodules on her trunk. Left axillary lymph node dissection and excision of two subcutaneous nodules were performed, and histopathology confirmed melanoma metastases in the lymph nodes and fibro-adipose tissue.

In September 2012, on routine follow-up, CT scans revealed metastases in the mediastinal lymph nodes and cutaneous metastasis in the anterior abdominal wall. A brain MRI showed multiple left parietal and right occipital region metastases. In October 2012,

the patient underwent whole-brain radiotherapy and commenced dacarbazine (DTIC) chemotherapy with a good initial response. In October 2013, a brain MRI revealed new metastasis in the left parietal region. Excision of the brain metastasis was performed, and the patient received five cycles of whole-brain radiotherapy. Stereotactic radiosurgery was not available in our country at that time.

There were no new metastases during the follow-up until January 2017, when thoracic and abdominal CT scans showed several metastases in the lungs (up to 5 mm), a lymph node conglomerate of 8 × 4 cm below the left adrenal gland infiltrating the psoas muscle, and a metastatic mass extending caudally from the lower pole of the left kidney. In addition, the patient reported swelling and pain in her left knee, and MRI of the left knee showed a metastatic mass in the left knee pit.

In March 2017, the patient started treatment with pembrolizumab 2 mg/kg once every 3 weeks. After six cycles of treatment, the patient presented with depigmented and hypopigmented macules and patches with well-defined borders on the genital region and eyelids with depigmentation of the eyelashes and eyebrows.

In August 2017, after nine cycles of pembrolizumab, the patient achieved a complete tumor response. During a routine skin examination, 23 months after initiating pembrolizumab treatment, scaly, erythematous, intensely pruritic papules were observed on the forearms, flexor wrists, legs, and dorsum of the feet (Fig. 1). In addition, almost total skin depigmentation was noted. Examination showed normal-appearing oral and genital mucosa. Dermoscopy of the skin lesions revealed a fern-leaf appearance on an erythematous background with white pearly structures corresponding to Wickham's striae, one of the main clinical features of lichen planus (Fig. 2). A skin lesion biopsy was performed, and the histology was consistent with lichen planus (Fig. 3A). For several

✉ Corresponding author: storebarce@gmail.com

weeks, acitretin 25 mg/day was commenced alongside with topical mometasone furoate ointment. The patient received acitretin during a 6-month period, and complete regression of the skin lesions was achieved. At the routine follow-up visit, CT scans of the chest and abdomen and a brain MRI showed no signs of the disease. The skin lesions were in complete remission.

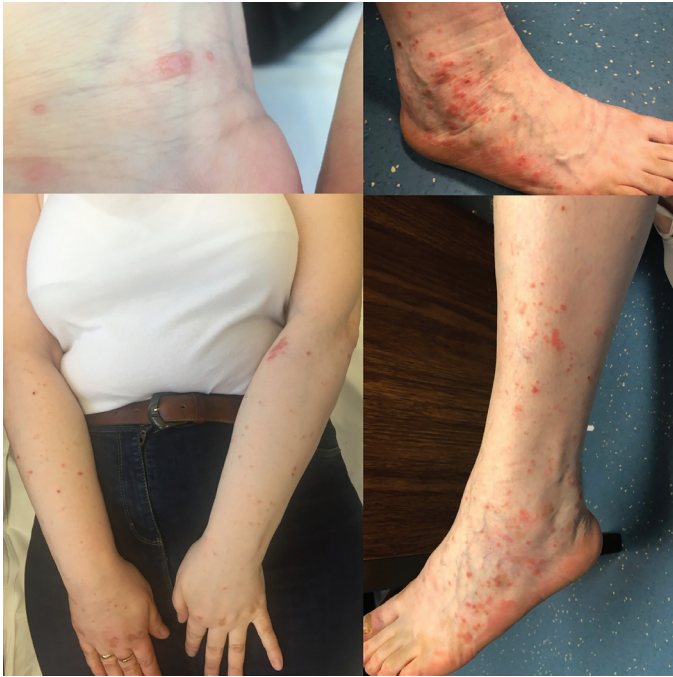

Figure 1 | Scaly erythematous papules on the flexor wrist, dorsal foot, forearms, and legs.

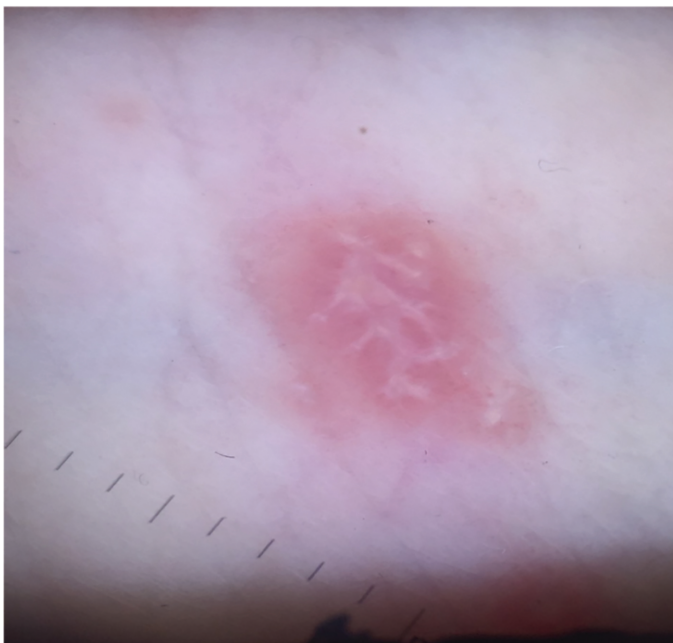

Figure 2 | Dermoscopic photo of the skin lesion: fern-leaf appearance on an erythematous background with white pearly structures corresponding to Wickham's striae, one of the main clinical features of lichen planus.

Case 2

The second patient was a 70-year-old male that presented with a pigmented nodular lesion on his left scapular region in 2005. A total surgical excision and histopathology were consistent with

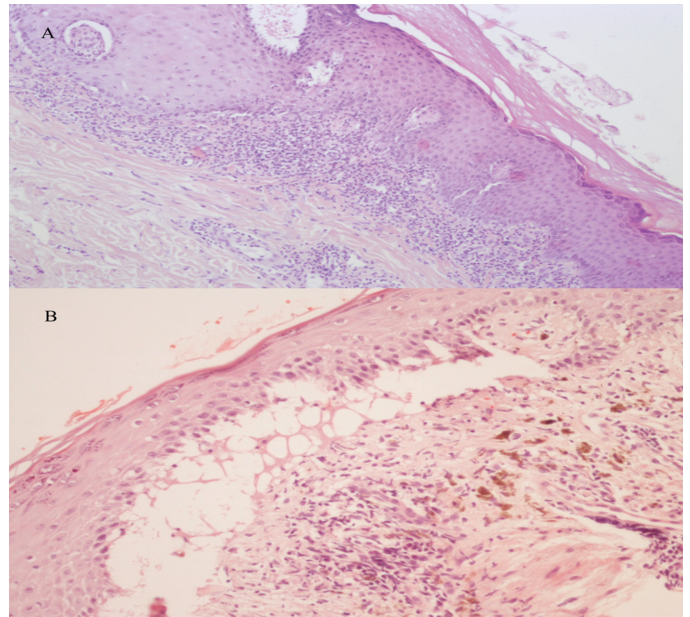


Figure 3 | Histology of biopsied skin lesions: A) Case 1: acanthosis, interface dermatitis, sawtooth rete ridges, hypergranulosis and hyperkeratosis without parakeratosis, and no eosinophils in the dermis—findings specific for lichen planus; B) Case 2: focal hypergranulosis, mild hyperkeratosis, without parakeratosis and in one part acanthosis of the epidermis. In the papillary dermis, there is an infiltration of inflammatory cells consisting of lymphocytes and histiocytes in a lichenoid pattern along with pigmentary incontinence—findings specific for lichen planus.

nodular melanoma with a Breslow thickness of 3.6 mm and presence of ulceration. After performing wide local excision and sentinel lymph node biopsy, a complete left axillary lymph node dissection was carried out. Histopathology demonstrated metastatic melanoma in one lymph node. In March 2012, a routine skin examination revealed a new dark-pigmented lesion on the patient's back. A total surgical excision was performed, and histopathology confirmed melanoma in situ.

In July 2018, the patient presented with speech and cognitive impairment. A brain CT scan demonstrated an expansive lesion in the left temporal region. Excision of the brain lesion was performed, and histopathologic analysis confirmed melanoma metastasis. *BRAF* V600E mutation was not detected.

In October 2018, on routine follow-up, a thoracic CT scan revealed a new well-defined pulmonary nodule in the lingula measuring 21 × 12 mm and a brain CT scan showed an annular contrast-enhancing lesion in the left temporal region. In December 2018, the patient underwent whole-brain radiotherapy, receiving a total dose of 30 Gy administered in 10 fractions, followed by initiation of pembrolizumab treatment at a dose of 2 mg/kg once every 3 weeks.

In May 2019, after seven cycles of pembrolizumab, the patient presented with pink scaly papules on the flexor wrist and dorsum of the hands and fine web-like white lines on the buccal mucosa (Fig. 4). A biopsy of the skin lesion was performed, and histological examination revealed characteristics of lichen planus (Fig. 3B). Topical betamethasone dipropionate ointment was initiated for several weeks with complete regression of skin lesions.

On a follow-up visit, after 13 months of pembrolizumab treatment, a thoracic CT scan showed several micronodular lesions in the right lung, whereas brain and abdomen CT scans showed no signs of the disease.

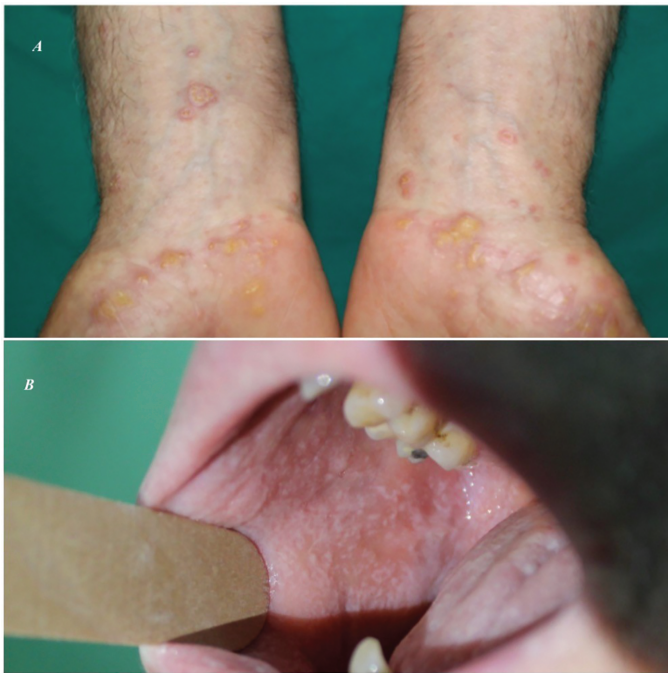

Figure 4 | A) Scaly, erythematous papules on the flexor wrists; B) fine web-like white lines on the buccal mucosa.

Discussion

The occurrence of cutaneous irAEs is frequent among patients receiving ICI therapy, with pruritus, eczema, lichenoid drug reactions, and vitiligo being the most commonly reported skin manifestations (2–5). However, vitiligo is primarily seen in patients being treated for metastatic melanoma (4, 5). Lichen planus, a persistent mucocutaneous disease characterized by immune-mediated chronic inflammation, presents with polygonal, violaceous papules covered in reticular white lines known as Wickham's striae. The specific underlying cause of lichen planus is still uncertain, but it is believed to involve cytotoxic CD8+ T cells inducing keratinocyte apoptosis through an unidentified antigen (6).

The administration of anti-PD1 agents, which block PD-L1, leads to T cell activation throughout the body, resulting in immune-related adverse events in multiple organs. In the case of lichen planus, it is hypothesized that the activation of auto-reactive lymphocyte clones targeting keratinocytes triggers their apoptosis and basal layer vacuolar degeneration (7). Notably, lichen planus is not commonly reported as an irAE in individuals undergoing anti-PD-1 therapy, and distinguishing it from lichenoid drug reactions can be challenging due to similar clinical and histological presentations (8, 9).

Lichen planus and lichenoid reactions are persistent inflammatory conditions triggered by T cells reacting to an unidentified antigen. These reactions are commonly linked to various medications, including beta-blockers, antimalarials, proton-pump inhibitors, and antihypertensive drugs (10).

During pembrolizumab treatment, our patients demonstrated typical lichen planus lesions with typical distribution and characteristic dermoscopic features: fern-leaf appearance on an erythematous background with white pearly structures corresponding to Wickham's striae—a feature rarely seen in lichenoid drug reactions (11). Both of our patients had no history of other significant medical conditions or daily intake of medications. Histopathology of the biopsied skin lesions showed acanthosis, interface derma-

titis, sawtooth rete ridges, hypergranulosis and hyperkeratosis without parakeratosis, and no eosinophils in the dermis, all findings specific for lichen planus. Unlike lichen planus, the histologic picture of lichenoid drug reaction often shows eosinophils in the dermal infiltrate, focal parakeratosis, focal disruption of the granular layer, and colloid bodies in the stratum corneum and granular layer (11). These findings highlight the necessity of skin biopsy in patients with ICI-induced lichenoid eruptions.

The primary treatment approach for lichen planus involves the use of topical corticosteroids. In patients that do not respond sufficiently to topical steroids and have more widespread disease with intensive symptoms (pruritus), other treatment options such as oral retinoids (acitretin), phototherapy, or systemic corticosteroids may be considered as beneficial options (6). The approach to treating lichenoid drug reactions involves cessation of the implicated drug if possible, usage of topical corticosteroids, and administration of oral or intravenous corticosteroids in severe cases (12). In the first case, our patient exhibited broader areas of lesions accompanied by intense pruritus. The lesion severity was categorized as grade 2 according to the CTCAE 5 (Common Terminology Criteria for Adverse Events version 5) for skin and subcutaneous tissue disorders. Therefore, a treatment regimen involving acitretin combined with topical corticosteroids was administered. In the second case, in which skin lesions were confined to the hands, flexor wrist, and mucosae (CTCAE 5, grade 1), treatment consisted solely of topical corticosteroids. Both of our patients experienced complete resolution of skin lesions over the course of several weeks to several months.

As far as we know, our first case report represents the first documented occurrence of both lichen planus and vitiligo in a single individual undergoing pembrolizumab treatment for metastatic melanoma. Various literature sources show that around 8% of patients treated with anti-PD1 or a combination of ICIs develop vitiligo (13). However, according to one small study published in 2016, vitiligo occurs more frequently with pembrolizumab than with other ICIs (25% of patients developed vitiligo) (14). Significantly, vitiligo has been linked to positive clinical outcomes in melanoma patients that undergo immunotherapy (14, 15). In another study by Freeman et al., it was shown that patients with metastatic melanoma treated with nivolumab and experiencing cutaneous toxicities, such as vitiligo, exhibited longer progression-free survival (16).

After 6 months of treatment, our first patient achieved complete response with no signs of the disease almost 6 years later. Research findings have suggested that certain individuals with metastatic melanoma may achieve long-lasting complete remission, even after stopping pembrolizumab, with a minimal recurrence rate observed over an average follow-up period of around 2 years (17).

Conclusions

Further research is necessary to determine optimal treatment duration, cessation timing after achieving complete remission, and predictive factors for achieving and maintaining long-lasting complete remission in patients with metastatic melanoma. Furthermore, exploring the prognostic significance of cutaneous irAEs, apart from vitiligo, in individuals treated with ICIs is of great importance.

References

1. Hamid O, Robert C, Daud A, Hodi FS, Hwu WJ, Kefford R, et al. Five-year survival outcomes for patients with advanced melanoma treated with pembrolizumab in KEYNOTE-001. *Ann Oncol*. 2019;30:582–8.
2. Bajwa R, Cheema A, Khan T, Amirpour A, Paul A, Chaughtai S, et al. Adverse effects of immune checkpoint inhibitors (programmed death-1 inhibitors and cytotoxic T-lymphocyte-associated protein-4 inhibitors): results of a retrospective study. *J Clin Med Res*. 2019;11:225–36.
3. Hofmann L, Forschner A, Loquai C, Goldinger SM, Zimmer L, Ugurel S, et al. Cutaneous, gastrointestinal, hepatic, endocrine, and renal side-effects of anti-PD-1 therapy. *Eur J Cancer*. 2016;60:190–209.
4. Sibaud V. Dermatologic reactions to immune checkpoint inhibitors. *Am J Clin Dermatol*. 2018;19:345–61.
5. Hwang SJE, Carlos G, Wakade D, Byth K, Kong BY, Chou S, et al. Cutaneous adverse events (AEs) of anti-programmed cell death (PD)-1 therapy in patients with metastatic melanoma: a single-institution cohort. *J Am Acad Dermatol*. 2016;74:455–61.e1
6. Chuang TY, Stille L. Lichen planus. *Medscape* [Internet]. [cited 2023 Jun 26] Available from: <http://emedicine.medscape.com/article/1123213-overview>.
7. Freeman GJ, Long AJ, Iwai Y, Bourque K, Chernova T, Nishimura H, et al. Engagement of the PD-1 immunoinhibitory receptor by a novel B7 family member leads to negative regulation of lymphocyte activation. *J Exp Med*. 2000;192:1027–34.
8. Denny J, Chong H, Akhras V. Lichen planus in a patient treated with pembrolizumab for metastatic malignant melanoma. *Clin Exp Dermatol*. 2018;43:354–6.
9. Schmidgen MI, Butsch F, Schadmand-Fischer S, Steinbrink K, Grabbe S, Weidenthaler-Barth B, et al. Pembrolizumab-induced lichen planus pemphigoides in a patient with metastatic melanoma. *J Dtsch Dermatol Ges*. 2017;15:742–5.
10. Lee M, Seetharamu N. An atypical presentation of lichen planus–like reaction from pembrolizumab. *Case Rep Dermatol Med*. 2019;4065437.
11. Gupta L, Kumar R. Lichen planus versus lichenoid drug reaction. *Indian J Drugs Dermatol*. 2015;1:44–5.
12. Brauer J, Votava HJ, Meehan S, Soter NA. Lichenoid drug eruption. *Dermatol Online J*. 2009;15:13.
13. Belum VR, Benhuri B, Postow MA, Hellmann MD, Lesokhin AM, Segal NH, et al. Characterisation and management of dermatologic adverse events to agents targeting the PD-1 receptor. *Eur J Cancer*. 2016;60:12–25.
14. Hua C, Boussemart L, Mateus C, Routier E, Boutros C, Cazenave H, et al. Association of vitiligo with tumor response in patients with metastatic melanoma treated with pembrolizumab. *JAMA Dermatol*. 2016;152:45–51.
15. Teulings HE, Limpens J, Jansen SN, Zwinderman AH, Reitsma JB, Spuls PI, et al. Vitiligo-like depigmentation in patients with stage III–IV melanoma receiving immunotherapy and its association with survival: a systematic review and meta-analysis. *J Clin Oncol*. 2015;33:773–81.
16. Freeman-Keller M, Kim Y, Cronin H, Richards A, Gibney G, Weber JS. Nivolumab in resected and unresectable metastatic melanoma: characteristics of immune-related adverse events and association with outcomes. *Clin Cancer Res*. 2016;22:886–94.
17. Robert C, Ribas A, Hamid O, Daud A, Wolchok JD, Joshua AM, et al. Durable complete response after discontinuation of pembrolizumab in patients with metastatic melanoma. *J Clin Oncol*. 2018;36:1668–74.